

Hypertelorism Correction: What Happens with Growth? Evaluation of a Series of 95 Surgical Cases

Daniel Marchac, M.D.
 Shawkat Sati, M.D.
 Dominique Renier, M.D.
 Jordan Deschamps-Braly,
 M.D.
 Alexandre Marchac, M.D.
Paris, France; and Amman, Jordan



Background: This report documents the authors' experience with 95 hypertelorism corrections performed since 1971. The authors note their findings regarding outcomes, preferred age at surgery, technique, and stability of results with growth.

Methods: Patients were classified into three groups: midline clefts (with or without nasal anomalies, Tessier 0 to 14); paramedian clefts (symmetric or asymmetric with or without nasal anomalies); and hypertelorism with craniosynostosis. The authors developed a hypertelorism index to measure longitudinal orbital position.

Results: A total of 70 box osteotomies were performed. Twelve of 95 patients had a bipartition. Six of 95 patients underwent a unilateral orbital box displacement or a three-wall mobilization, and seven of 95 had a medial wall osteotomy. Eighty patients were graded 1 to 4 using the Whitaker scale. Fifty-nine of 80 patients received a grade of 1, 15 patients received a grade of 2, five patients received a grade of three, four patients initially scored a 4, and three patients underwent reoperation and were rescored as 1. The authors developed a hypertelorism index to rate 28 patients with long-term follow-up. None showed deterioration of results over the long term. The complication rate was 4 percent.

Conclusion: The most interesting finding was that an initially good result in terms of orbital correction, whatever the severity, remains good with time, and facial balance improves after completion of growth. (*Plast. Reconstr. Surg.* 129: 713, 2012.)

CLINICAL QUESTION/LEVEL OF EVIDENCE: Therapeutic, IV.

Radical mobilization of the orbits to correct increased interorbital distance is a spectacular and rewarding operation for the craniofacial surgeon. We observed Paul Tessier perform his first orbital mobilization using an intracranial approach in 1963.¹ After that, we performed our first correction in 1971. This report details our cumulative experience of 95 cases.

Many points are discussed. What is the best age for surgery? What is the best approach to dealing with the nose? Should one preserve the dorsum using paramedian resections, or resect the central portion using a bone graft to reconstruct the nose? Under what circumstances should an infracranial or medial wall osteotomy be used rather than full

mobilization of the orbits by means of a transcranial approach? In addition, questions regarding growth are still not adequately answered. For instance, what is the consequence of these operations that involve a nasoseptal resection on maxillary growth? Is there deterioration of the result with growth and time, and is an early correction during infancy possible or wise? By analyzing this series and considering previous studies²⁻⁷ of hypertelorisms that have been operated on, we are attempting to answer these questions.

Hypertelorism is characterized by an increase in interorbital distance. Hypertelorism is not a syndrome but simply a physical finding in many craniofacial anomalies. In 1924, Greig⁸ introduced the term "ocular hypertelorism" at the

From the Craniofacial Unit, Hôpital Necker Enfants Malades, Surgical Office.

Received for publication May 10, 2011; accepted September 21, 2011.

Copyright ©2012 by the American Society of Plastic Surgeons

DOI: 10.1097/PRS.0b013e3182402db1

Disclosure: *The authors have no financial interest to declare in relation to the content of this article.*

Struthers Lecture of The Royal College of Surgeons of Edinburgh. He described two cases of congenital facial deformity with a “Great breadth between the eyes.” Tessier⁹ introduced in 1972 the more accurate term “orbital hypertelorism” to denote true lateralization of the entire orbital complex (i.e., both the medial and lateral walls). Nevertheless, hypertelorism has become an accepted synonym for orbital hypertelorism.

Tessier et al.¹ and Converse et al.¹⁰ have suggested that “Enlargement of the ethmoid cells and bone would appear to be the cause” of hypertelorism. Morin et al. showed that 50 percent of interorbital growth occurs by 3 years of age, followed by a more gradual widening until completion of growth.¹¹ Sarnat and Bradley have concluded that 90 percent of facial growth is reached by 6 years of age.¹²

HISTORY OF TREATMENT

When presented with a patient having severe orbital hypertelorism, Paul Tessier early in his career realized that nothing short of complete mobilization of the orbits could correct this malformation. He also understood the necessity of having access to the skull base from an intracranial approach. Gerard Guyot, Tessier’s neurosurgical colleague at Hopital Foch, when asked whether he thought this could be done, replied in iconic form “*Pourquoi pas?*” (why not?). For their first case, they performed a first-stage procedure with a dermal graft on the dura of the anterior cranial fossa, for

fear of infection. This was subsequently abandoned after the first successful cases in 1963. Tessier noted at that time that this operation was only possible because the optic canals are in relatively normal position and surgical intervention would not place undue risk to the optic nerve.⁹

The principles of total mobilization of the orbits with a central resection introduced by Paul Tessier in 1967 are still valid today.¹ In addition, other techniques have been introduced since that time. Converse et al.¹⁰ described in 1968 how to preserve the olfactory nerves, and Jacques van der Meulen¹³ described the facial bipartition in 1983 that brings together the two mobilized hemifacial segments. In 1986, we began using two lateral frontal spurs for positioning and immobilizing the superior orbits¹⁴ instead of the frontal “bandeau” of Paul Tessier¹⁵ (Figs. 1 and 2).

PATIENTS AND METHODS

Clinical Classification

Between 1971 and 2010, 95 patients underwent surgical correction performed by the senior author (D.M.) for congenital hypertelorism. True hypertelorism is seen with a number of congenital deformities. We have divided them into four useful categories for study, as follows:

1. Midline clefts: symmetric, with or without nasal anomalies.
2. Paramedian clefts: symmetric or asymmetric, with or without nasal anomalies.

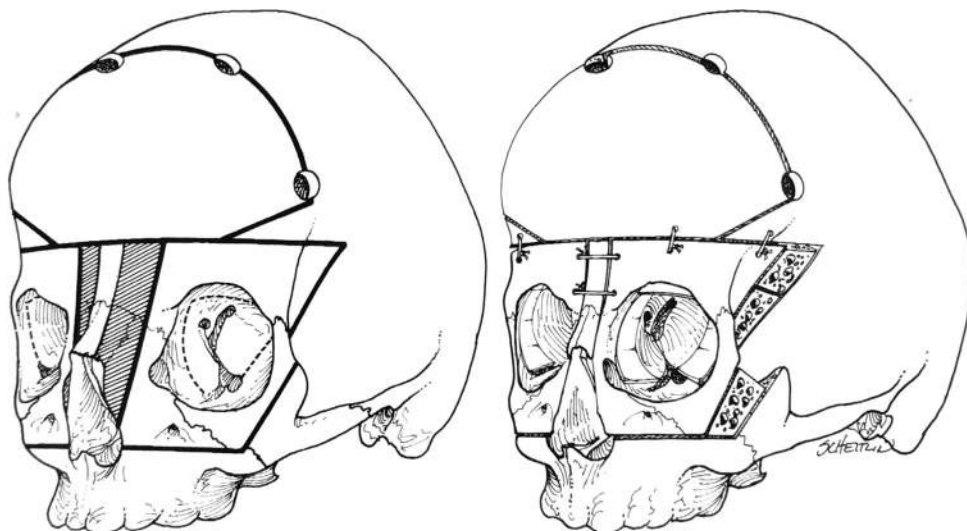


Fig. 1. (Left) Drawing of the four-wall box osteotomy with preservation of the nasal bones when they are normal. (Right) Drawing of the two lateral spurs, allowing precise stabilization and fixation. (Reprinted with permission from Marchac D, Renier D. Congenital craniofacial malformations. In: Youmans JR, ed. *Neurological Surgery*. Vol. 2. Philadelphia: Saunders; 1996:1012–1034.)

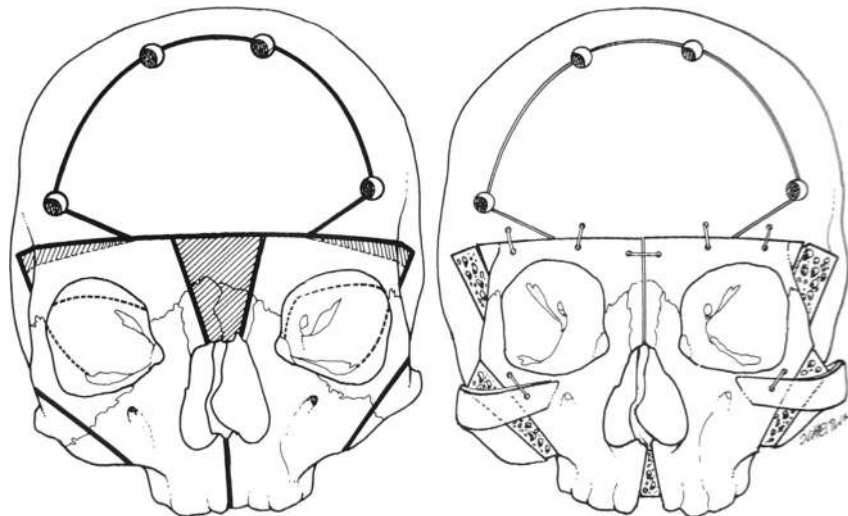


Fig. 2. (Left) Drawing of a bipartition; a V midline excision is performed with a midline split of the palate. (Right) The lateral spurs allow positioning of the orbits after displacement. (Reprinted with permission from Marchac D, Renier D. Congenital craniofacial malformations. In: Youmans JR, ed. *Neurological Surgery*. Vol. 2. Philadelphia: Saunders; 1996:1012–1034.)

3. Hypertelorism with associated craniosynostosis (brachycephaly, plagiocephaly): Tessier¹⁶ considered patients with hypertelorism and coronal synostosis to be a separate group that he called BETS (where B is brachycephaly, E is euprosopia, T is telorbitism, and S is scapho-maxillism). It is also called craniofrontonasal dysplasia.^{6–15}
4. Other: hypertelorism associated with acrocephalosyndactyly (Apert syndrome), and hypertelorism associated with frontonasal encephaloceles or midline dermoid cysts. This group was excluded, as they are beyond the scope of this article.

Preoperative Severity Grading

Preoperative severity grading of patients was assessed using the distance between the lacrimal crests as described by Gunther¹⁷ and Tessier.¹⁶

1. Mild (first-degree): 30 to 34 mm.
2. Moderate (second-degree): 35 to 39 mm.
3. Severe (third-degree): 40 mm or greater.

The Whitaker classification¹⁸ was used to standardize aesthetic outcomes. Preoperative assessment includes frontal cephalograms and computed tomography with three-dimensional reformat. Also, coronal views are necessary to determine the level of the cribriform plate. Contrast is used to enhance the brain parenchyma. Three-dimensional imaging is used to plan the surgery.¹⁹ Vision, hearing, and air-

way problems are evaluated, in addition to cognitive development.

Measurements are taken of the intercanthal distance and the interpupillary distance. The positions of the canthus, eyebrows, and frontal hairline are noted, as are the occlusal relationship and the palate, nose, and lip anatomy. A general physical examination is included in the assessment.

Evaluation of the Relationship of the Orbits and Intercanthal Distance with Growth: A Hypertelorism Index

A key issue in assessing outcomes is a reproducible technique with which to assess intercanthal distance after surgical correction. We have developed a method of measuring the relationship of the palpebral fissure against the intercanthal distance. In a Caucasian adult, the width of the palpebral fissure (from the external canthus to the internal canthus) is equal to the intercanthal distance.²⁰ The ideal ratio is as follows: [intercanthal distance (en-en)]/[palpebral fissure (ex-en)] = 1 (Fig. 3). When the intercanthal distance is increased, this ratio increases. This hypertelorism index, (en-en)/(ex-en), reflects the soft-tissue relationship and the bony relationship.

We used Photoshop CS4 (Adobe Systems, Inc., San Jose, Calif.) to measure the left palpebral fissure (ex-en) and the intercanthal distance (en-en). Standardized preoperative photographs were taken, as were photographs up to skeletal matu-

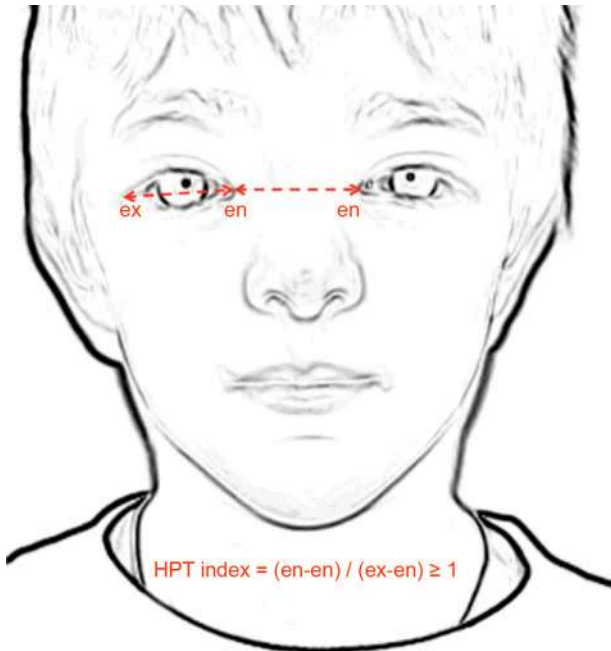


Fig. 3. The hypertelorism index. The distance between the medial canthi and the width of the palpebral fissure are measured and analyzed using Photoshop CS4.

Frontal view photographs at these different times were imported into Photoshop and superimposed onto a single layer. The ruler tool was used to measure the left palpebral fissure (en-ex) followed by the intercanthal distance (en-en). Photoshop gives a value that is not an absolute value. The value varies according to picture and screen resolution. However, the numerical value it gives is stable with regard to forming a ratio when used within the same image. In addition, this technique, because it compares two distances on the same photograph that are in very close proximity to one another, virtually eliminates error caused by parallax or focal length.

We repeated the measurement on preoperative images, those obtained at approximately 6 months postoperatively, and those obtained at skeletal maturity. We noted these data and analyzed them using Excel 2011 (Microsoft Corp., Redmond, Wash.). Patients were excluded from the hypertelorism index substudy if they had not reached skeletal maturity at the time of this study or if their records were in some way not usable as in Figure 4. The second measurement must be taken at least a few months after surgery. The reason is that on-table measurements or early postoperative measurements do not reflect a consolidated result.

Subjective Outcome Analysis

The Whitaker classification¹⁸ was used to standardize aesthetic outcomes as follows:

- Category I: No refinement or surgical revision considered advisable or necessary.
- Category II: Soft tissue or lesser bone-contouring revisions were advisable (such as nasal bone grafting); could be performed on an outpatient basis or with a maximum 2-day hospitalization.
- Category III: Major osteotomies or bone graft repositioning, onlay bone grafts; these procedures were not as extensive as the original operation.
- Category IV: A major craniofacial procedure was advisable, duplicating or exceeding the original operation.

Surgical Technique

A coronal incision is performed with a zigzag pattern. Subperiosteal dissection is then performed moving forward over the forehead for exposure of the upper portions of the orbit and nasal bones. A frontal bone flap is designed to leave a 1-cm strip across the top of the orbits; however, a lateral spur is maintained that ends at the medial portion of the orbits (Figs. 1 and 2). Craniotomy is then performed. Careful epidural dissection is performed under direct vision around the anterior cranial fossa and over the lateral aspects of the cribriform plate. Any dural tears that occur are repaired either primarily or by using a periosteal patch. We also use fibrin glue as an adjunct to dural tear repair.²¹ In addition, we dissect the nasal mucosa free from under the nasal bones and repair any mucosal lacerations.

We then design the medial resection. The design allows for keeping 6 mm of bone on each side of the orbit for sturdy fixation. The shape of the resection is quadrangular in cases of planned box osteotomy. In cases of facial bipartition, the pattern usually forms a medial V-shaped wedge resection, with more bone removed cephalad than caudal. If the inner canthus are well defined and in normal anatomical position relative to their bony insertions, we do not disinsert them. If we have to disinsert the medial canthus, a transnasal wire is used to replace the medial canthus to its proper location at the end of the procedure.

When there is a normal nasal dorsum, we generally preserve the anatomy and opt for paramedian resection of bone rather than the standard midline bony resection. The septum is preserved in this circumstance. Most cases will require midline resection of the nasal septal complex because often the nasal bones are severely distorted. In the

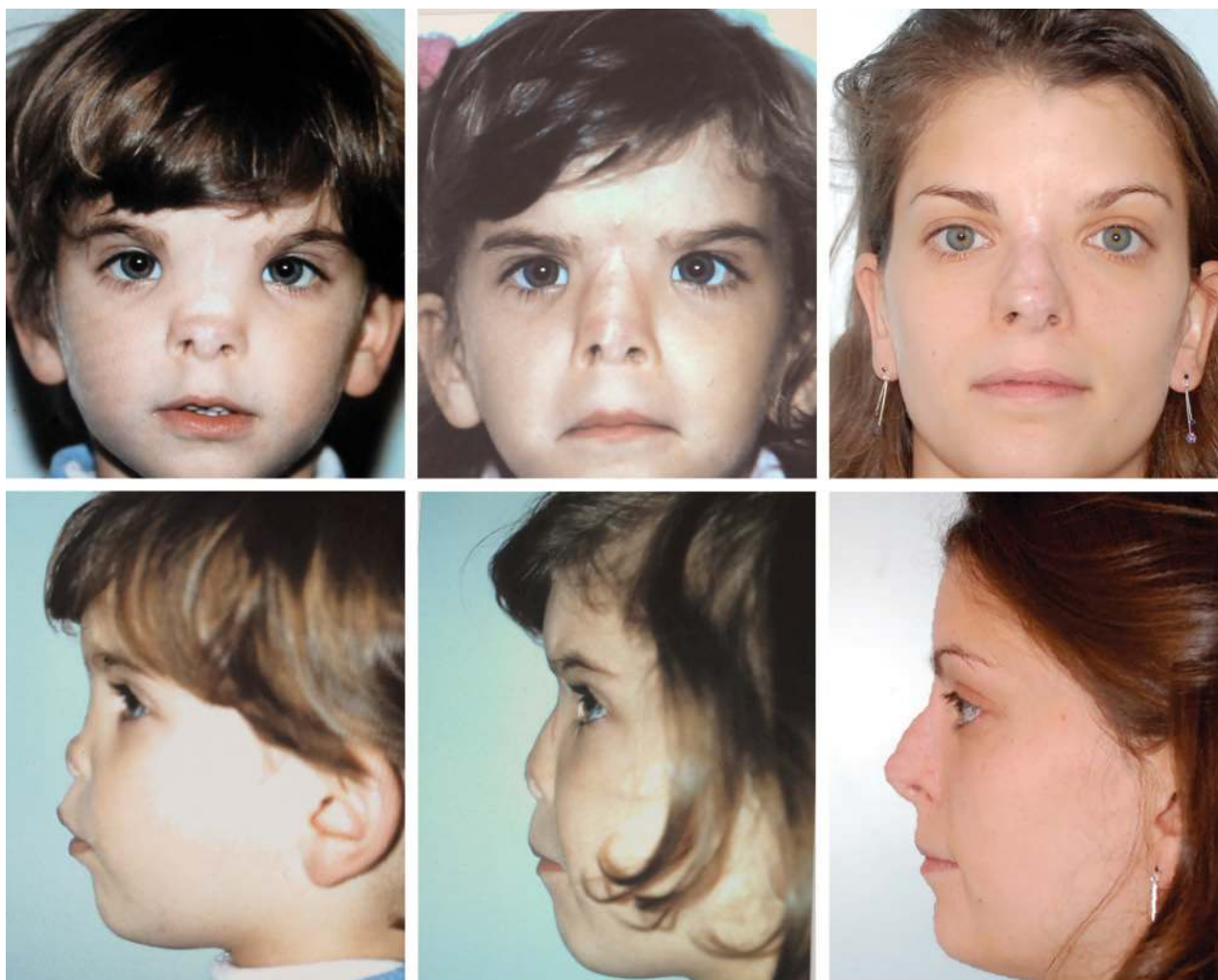

Fig. 4. (Left) A 3-year-old girl presented with severe hypertelorism and an extremely short nose. (Center) The patient is shown at 5 years of age, after box osteotomy and a V-Y flap to elongate the nose, with a bone graft. (Right) At 25 years of age, after several operations on the nose, mostly rib grafts, a revision of the dorsum is planned. This patient was not included in the hypertelorism index because of her severe epicanthal folds at 5 years of age. She is a good example of the improvements that can be obtained with soft-tissue corrections and nasal bone grafts. Note that there were no orbital revisions.

case of box osteotomies, a subciliary incision is planned to allow for a higher horizontal osteotomy at or above the level of the infraorbital nerve. Osteotomy at this level protects the nerve and the tooth buds. If a facial bipartition is planned, a small midline vestibular incision is made to allow for midline sectioning of the palate. In both cases, osteotomies of the medial and lateral orbital walls and the pterygomaxillary junction are performed from above through the coronal incision.

Once the orbits are fully mobilized, they are brought together in the midline and maintained using twisted wire as described by Paul Tessier. The lateral frontal spurs are used to help position the orbits at the correct anteroposterior position and to provide for firm fixation. Care is taken to

control the position and width of the orbital walls and the angulation of the lateral orbital walls. The medial orbital walls must be checked to ensure that there is not a stepoff at the osteotomy level and, if necessary, that the posterior medial wall is impacted.

Regarding treatment of the nose, in the case of medial excision of bone, we reconstruct the dorsum with a parietal cranial bone graft. When the tip of the nose is bifid, a direct transcolumellar approach is used to access the tip, and suture techniques are used to approximate the alar cartilages over the tip of the cranial bone graft. After medialization of the orbits, there is always too much skin in the midline. The skin is dealt with by stay sutures, with or without fibrin glue.²² Occa-

sionally, a medial skin resection is performed using meticulous suture techniques. This usually leads to a barely visible scar that is quite acceptable to patients. Before closure, we resuspend the temporalis muscle using sutures and also perform a lateral canthopexy. The frontal bone flap is replaced into proper position and fixed with resorbable sutures or plates. A tarsorrhaphy placed at the beginning of the case is left in place for 2 to 3 days to protect the globes and minimize conjunctival edema.

The infracranial osteotomy can be performed if the cribriform plate is located in a high position. In cases of mild hypertelorism, one can perform a mobilization of the medial walls after removal of the excess of nasal bone in the midline. Mobilization of the lower three orbital walls while leaving the orbital roofs in place can be used to correct moderate cases. The main question of control of the cranial base is usually addressed by performing a trephine hole at the glabella. We have performed six three-wall infracranial cases and seven medial wall osteotomies. One of them bled intracranially.

Statistical Analysis

An unpaired two-tailed *t* test was used to determine any significant differences between the hypertelorism index groups. To compare physician satisfaction scores between the two groups, the Mann-Whitney-Wilcoxon test was performed. A value of $p < 0.05$ was considered statistically significant.

RESULTS

Patient Demographics

Ninety-five patients were operated on in total. Seventy-two of 95 patients (75 percent) were treated at younger than 8 years. Twenty-three of 95 patients (24 percent) were treated at older than 8 years. Fifteen of 95 patients (15 percent) had inadequate long-term follow-up. These consisted of mostly foreign patients who either did not return for follow-up or were operated on abroad and were followed by a local physician. There are 80 patients (73 percent) remaining that had follow-up that could be used to assess outcome. The range of follow-up was from 1 to 27 years for those younger than 8 years (mean, 9.4 years). The range of follow-up for those older than 8 years was 1 to 19 years, with a mean of 4.7 years. The average age at the time of operation for those younger than 8 years was 5.1 years (range, 5 to 7 years) as compared with those older than 8 years, whose average age at surgery was 16.7 years (range, 9 to 27 years).

The diagnoses for those younger than 8 years are as follows: median cleft, $n = 45$ (63 percent); paramedian cleft, $n = 15$ (21 percent); and craniosynostosis associated with hypertelorism, $n = 12$ (17 percent). In the children older than 8 years, median cleft totaled 11 patients (48 percent), paramedian clefts totaled four (17 percent) patients, and craniosynostosis associated with hypertelorism numbered eight patients (35 percent).

Severity Score

Severity scores were evaluated by measuring the interorbital distances preoperatively. In the group younger than 8 years, seven of 72 patients (9.7 percent) were mild patients, 32 of 72 (44 percent) were moderate patients, and 33 of 72 (45 percent) were severe patients. Among the 23 patients older than 8 years, three (13 percent) were mild patients, 11 (47 percent) were moderate patients, and nine (39 percent) were severe patients. Looking at the relative percentages of each category within the older than 8-year and younger than 8-year groups, the composition of patients who were operated on in each category is similar.

Subjective Aesthetic Outcome

Overall aesthetic outcomes were judged by two of the authors. The Whitaker scale was used to grade the outcome.¹⁸ For the group younger than 8 years, 63 of 72 (87 percent) had adequate follow-up. The mean score for the mild group was 1.5, the moderate severity group had a mean score of 1.3, and the severe group had a mean score of 1.87. For the group older than 8 years, 17 of 23 patients (73 percent) had adequate follow-up. The mean scores were 1.0 for the mild group, 1.4 for the moderate severity group, and 1.6 for the severe group.

The nasal aesthetic outcome was judged using the same scale. Those younger than 8 years had a score of 1.2 for the mild group, 1.7 for the moderate group, and 1.9 for the severe group. Those older than 8 years had a score of 1 for the mild group, 1.2 for the moderate group, and 1.4 for the severe group.

The Whitaker scale¹⁸ was also used to stratify results based on technique. Those younger than 8 years who underwent box osteotomy had overall mean scores of 1.5, whereas those who had a facial bipartition before 8 years of age had a mean score of 1.9. Those who had a medial wall osteotomy had a score of 1, and those who underwent three-wall osteotomy also had a score of 1. In those older than 8 years, those who had a box osteotomy had a mean score of 1.6 and those with medial wall

osteotomy had a mean score of 2. Those who had a three-wall osteotomy had a score of 1.

Our results are listed in Table 1. Fernando Ortiz-Monasterio said that hypertelorism correction is simply a rhinoplasty performed through a transcranial approach.²³ The result of the nasal correction is very important, and we present some profile and frontal views of patients on whom we have operated (Figs. 4 through 6).

Does Hypertelorism Recur after Surgery? Results of Hypertelorism Index Analysis

Twenty-eight patients had sufficient follow-up to be included for analysis of the hypertelorism

index. The majority of these children were operated on before age 8 years and most were operated on at 5 years of age. The patient's hypertelorism index was calculated before surgery and then again at 6 months and at completion of facial growth. The mean hypertelorism index before surgery was 2.03. Six months after correction, the mean hypertelorism index score was 1.46, and after completion of growth, this value improved even further to 1.37 (Fig. 7).

The two-tailed *p* value between results at 6 months and results after completion of growth are 0.006 ($p < 0.05$). This finding is interesting in that it shows that the correction achieved is not only maintained over time but improves slightly without revising the orbital correction. Most patients had the benefit of epicanthal fold correction, canthopexy, and rhinoplasty. We attribute the improvement of orbital position to generalized facial growth, which minimizes any remaining hypertelorism (Figs. 4 through 6, 8, and 9).

Table 1. Results

	Younger than 8 Years	Older than 8 Years
Total no. of patients	72	23
Age, yr		
Mean	5.1	16.7
Range	5–7	9–27
Type of HPT		
Median cleft	45 (62%)	11 (48%)
Paramedial cleft	15 (21%)	4 (17%)
HPT associated with craniosynostosis	12 (17%)	8 (35%)
Severity		
Mild	7 (10%)	3 (13%)
Moderate	32 (44%)	11 (48%)
Severe	33 (46%)	9 (39%)
Surgical techniques		
Box osteotomy	52 (72%)	18 (78%)
Three-wall mobilization	3 (5%)	3 (13%)
Medial wall osteotomy	5 (7%)	2 (9%)
Bipartition	12 (17%)	0
HPT Whitaker score (mean)		
Total	1.7	1.4
Mild	63	17
Moderate	1.5	1
Severe	1.3	1.4
Severe	1.87	1.6
Mean rhinoplasty score		
Total	1.75	1.285
Mild	53	10
Moderate	1.2	1
Severe	1.7	1.2
Severe	1.9	1.4
Revision, %	20 (37%)	4 (40%)
Surgical technique score		
Box osteotomy	1.5 (<i>n</i> = 41)	1.6 (<i>n</i> = 10)
Bipartition	1.9 (<i>n</i> = 10)	NA
Medial wall osteotomy	1 (<i>n</i> = 5)	2 (<i>n</i> = 2)
Three-fourths wall osteotomy	1 (<i>n</i> = 1)	1 (<i>n</i> = 1)
Follow-up		
Mean	9.4 yr	4.65 yr
Range	1–27 yr	1–19 yr
No.	57	13
Complications, %	4 (5.5%)	1 (4%)

HPT, hypertelorism; NA, not applicable.

Secondary Procedures

It has been our experience that it was rare that no follow-up procedures were necessary. We divided the patients by the arbitrary age of 8 years to make a direct comparison with the results reported by Raposo-Amaral et al.⁷ even though the majority of our patients were operated on at 5 years of age.

Younger than 8 Years

When considering our revision rate, we have included only patients who have reached skeletal maturity. We have also included planned procedures that are needed but may not have occurred yet. Forty-one patients who were operated on before the age of 8 were able to be included in this assessment. Thirty-one required revisions and 10 patients did not require revisions. Three patients had a poor result, with a hypertelorism score of 4. Two of 41 patients (5 percent) had to undergo revision box osteotomy within 6 months of the initial operation that improved their hypertelorism index to 2. Four of 41 patients (10 percent) underwent Le Fort I osteotomy for maxillary hypoplasia. Eleven of 41 patients (27 percent) had epicanthal fold corrections at a separate procedure. Four of 41 patients (10 percent) underwent revision of midline skin excision. Sixteen of 41 patients (39 percent) underwent revision bone or cartilage grafting to the nose. Five of 41 patients (12 percent) underwent medial canthopexy. One girl had a zygomatic arch narrowing with a mentalis muscle disinsertion 10 years postoperatively

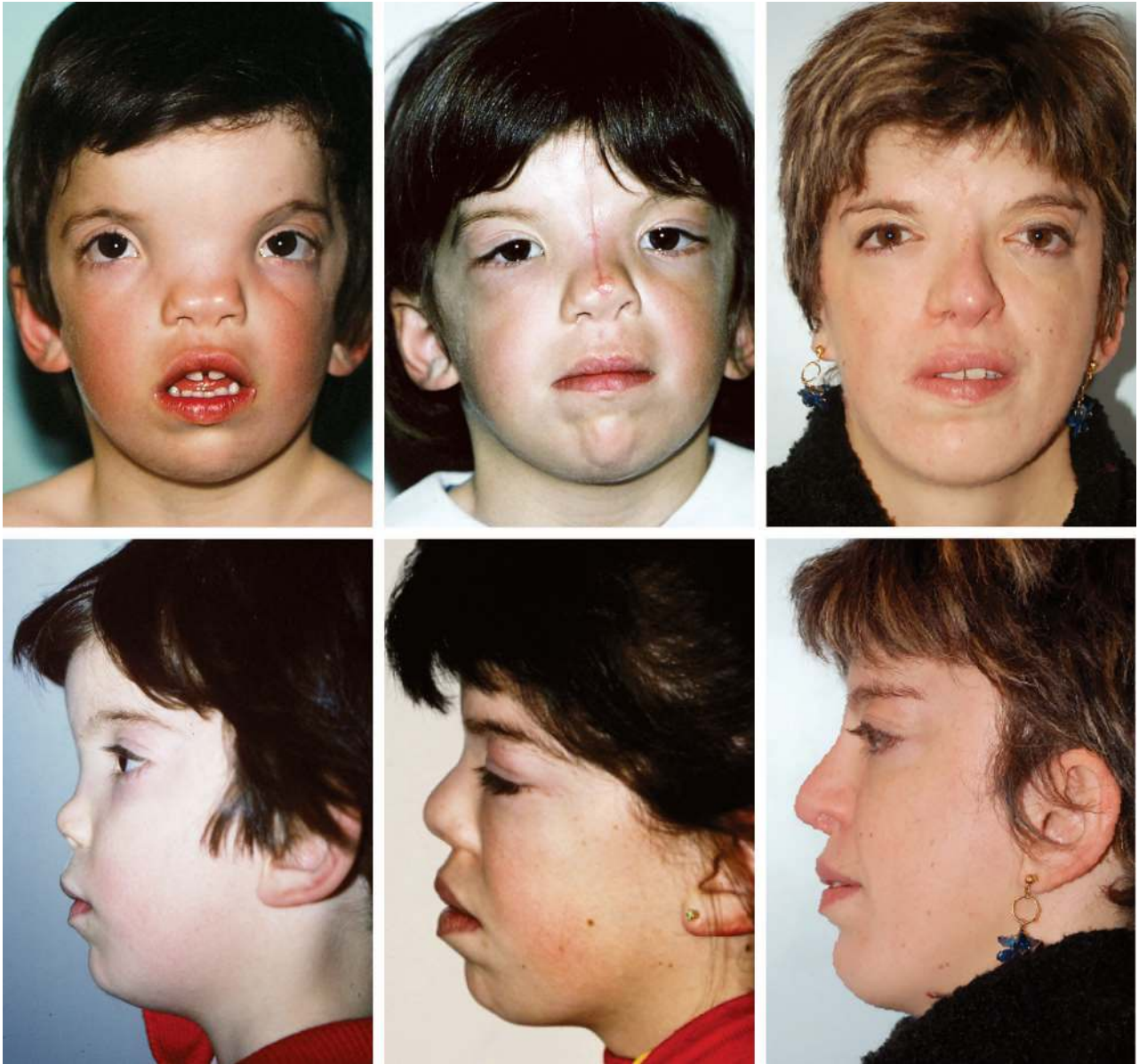

Fig. 5. (Left) A 5-year-old girl presented with a severe midline cleft. (Center) She is shown at 6 months after box osteotomy with central resection and bone graft—midline skin excision. (Right) At 26 years, the patient has undergone several revisions of the epicanthal folds and bone grafts to the nose.

to improve her facial proportions. Excluding the Le Fort osteotomies, 10 of 41 patients (24 percent) underwent some type of bony revision. The total number of revision procedures in this group was 50. The majority of these were minor revisions. Ten of 41 patients (24 percent) did not require any revision (Table 2).

Older than 8 Years

Eleven patients met the criteria and had adequate records with which to assess their secondary operations and had reached skeletal maturity. Again, we have also included procedures that are

required but have not yet been performed. One patient who had a poor result (hypertelorism score, 4) had to undergo a revision box osteotomy 6 months later that resulted in a hypertelorism score of 1. Two of 11 patients (18 percent) underwent epicanthal fold correction compared with (27 percent) in the group of patients younger than 8 years. Three of 11 patients (27 percent) required revision rhinoplasty, including bone or cartilage grafting, as compared with 39 percent in the those younger than 8 years. One of 11 patients (9 percent) underwent revision medial canthopexy,

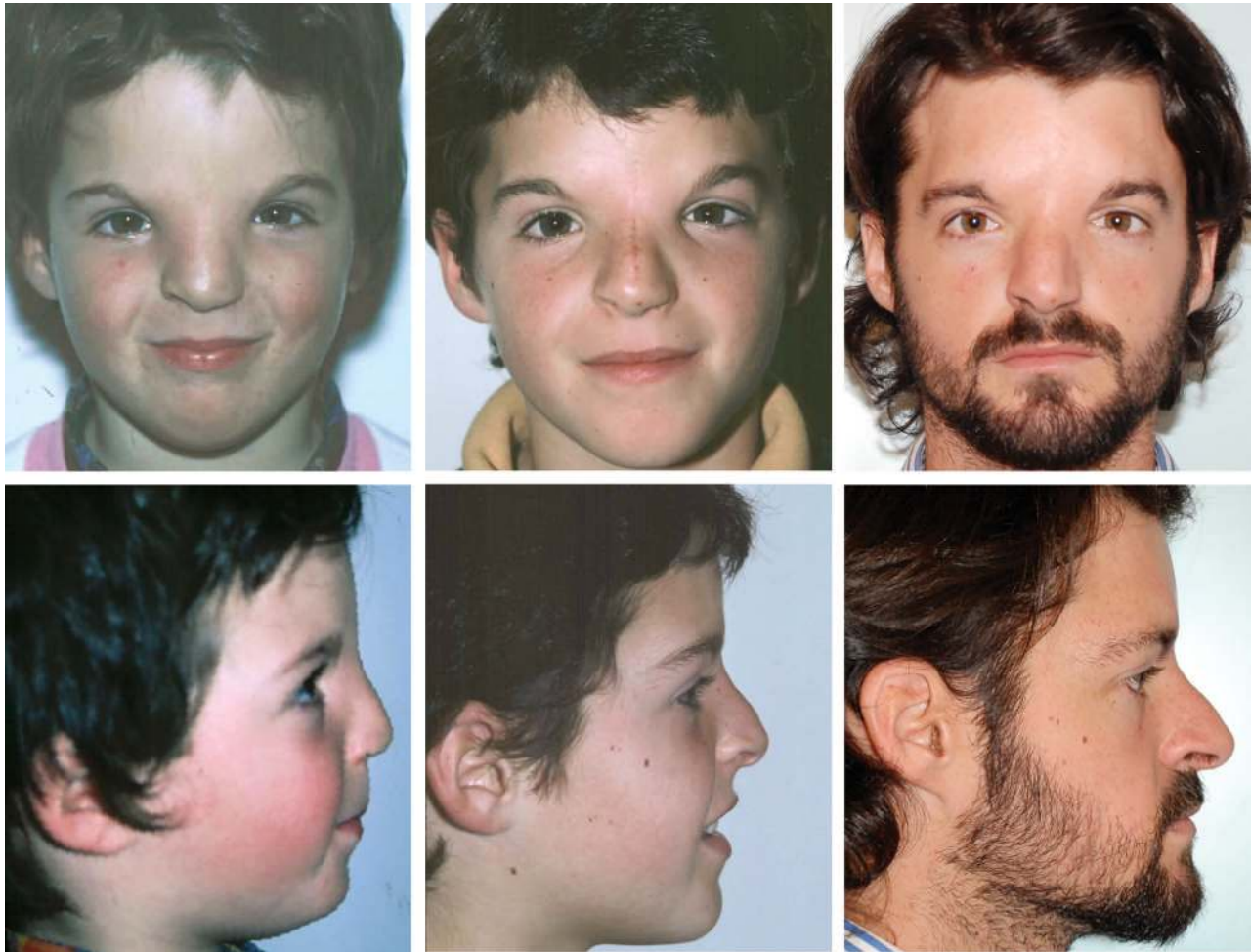

Fig. 6. (Left) A 5-year-old boy presented with a midline cleft. (Center) The patient is shown at age 8 years, after box osteotomy performed at age 5 years with nasal bone graft. A midline skin excision was performed and is still visible 3 years later. (Right) At age 28 years, with no revision, the nasal scar is not visible and the nose is normal.

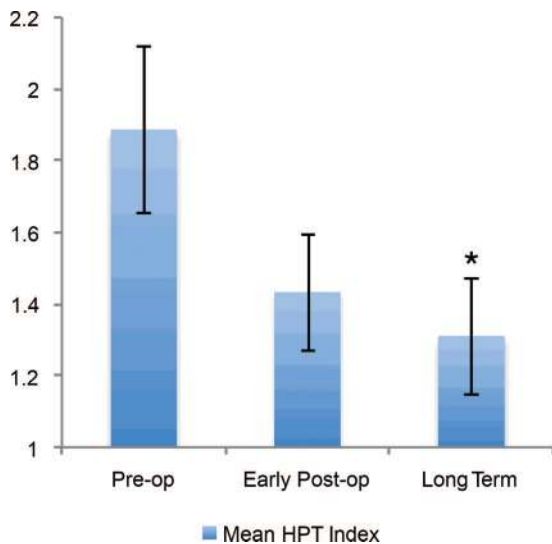


Fig. 7. Results of hypertelorism index calculation. The long-term correction is slightly better than the short-term result.

compared with 12 percent in those younger than 8 years. There was one patient (9 percent) who underwent Le Fort I osteotomy, compared with 10 percent in the group of patients younger than 8. The only bony revision performed was in the patient who underwent revision box osteotomy. The total number of revision procedures performed was nine. Four of 11 patients (36 percent) in the older age group did not require any revision, as compared with 24 percent in the younger age group (Table 2).

We wait 6 months to 1 year after surgery to evaluate our results. At that time, we find one of three situations.

1. The result is obviously not satisfactory, and a radical reoperation to bring the orbits closer together is indicated. We have encountered this situation in only four of 80 cases.

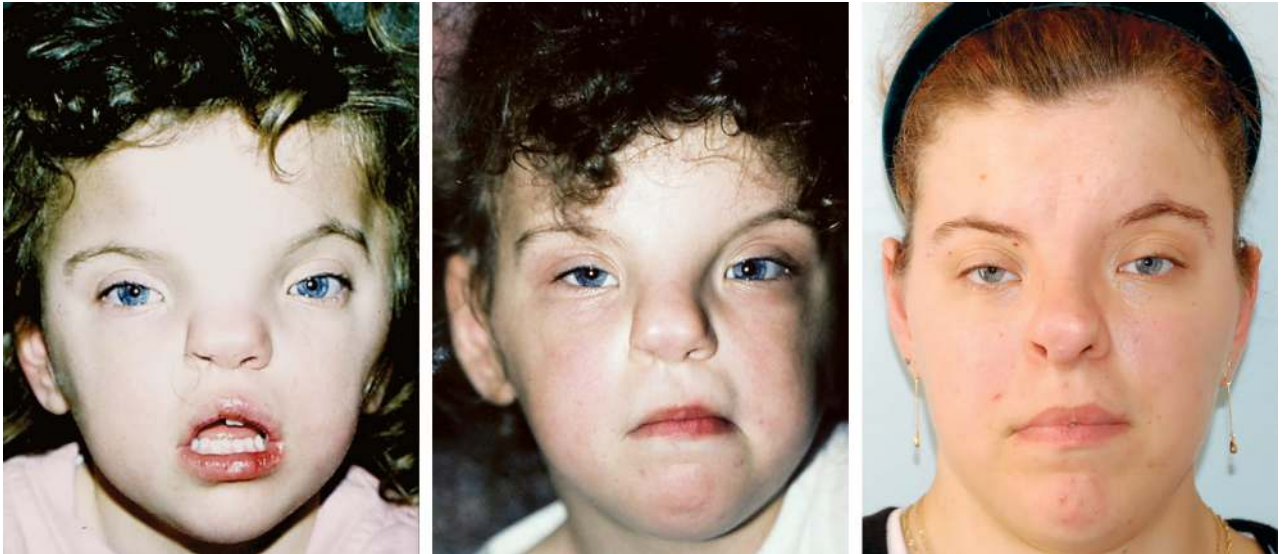

Fig. 8. (Left) A 2-year-old girl presented with craniofacial dysplasia. The brachycephaly had been corrected at 4 months. The patient is shown (center) at 6 years of age, 8 months after bipartition, and (right) at 19 years of age, after nasal bone graft.

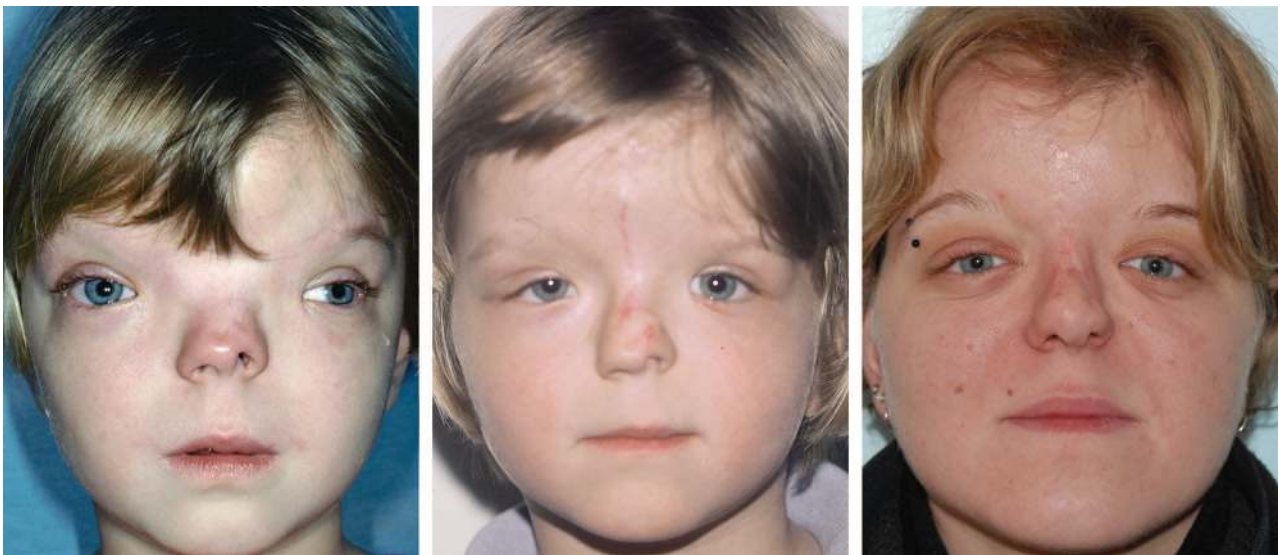

Fig. 9. (Left) The patient presented at 5 years of age showing severe hypertelorism with paramedial cleft and nasal anomaly. The patient is shown (center) at 6 years of age, 8 months after bipartition, and (right) at 27 years of age, after epicanthal fold correction, composite graft to the left nostril, and finally auricular cartilage grafts along the dorsum and resection of the right nostril on 2 mm.

2. The orbits are in an acceptable position, but there is too much skin at the level of the nasal dorsum with epicanthal folds. These cases have benefited by an epicanthal fold correction in 12 of 80 cases. Six of the 12 epicanthal fold revisions required revision of medial canthopexies (six of 80) and later a nasal augmentation. This nasal augmentation was performed in 19 of 80 cases with cartilage, cranial bone

graft, or rib graft with cartilage at the distal end. It is obvious that all these secondary operations improve the appearance of the patients; however, the main point we are making is that the repositioning of the orbits has been maintained.

3. The orbital correction is good, the nasal projection is good, and even if there is a tissue excess at the epicanthal region, it is minimal. With time, the appearance contin-

Table 2. Secondary Revisions

	Total	No. of Epicanthal Fold Corrections	No. of Nasal Bone Grafts	No. of Medial Canthopexies	No. of Bony Revisions	No. that Needed Excision of Excess Skin
No. of patients younger than 8 yr with revision	31	11	16	5	10	4
No. of patients younger than 8 yr not needing revisions	10	N/A	N/A	N/A	N/A	N/A
Total no. of patients younger than 8 yr with long-term follow-up	41					
Percentage of patients younger than 8 yr with revision by type		27	39	12	24	10
No. of patients older than 8 yr with revisions	7	1	3	1	1	2
No. of patients older than 8 yr not needing revisions	4	N/A	N/A	N/A	N/A	N/A
No. of patients older than 8 yr with long-term follow-up	11					
Percentage of patients older than 8 yr with revisions by type		9	27	9	9	18

N/A, not applicable.

ues to improve (Fig. 7). This was the result in 14 of 80 cases.

Complications

We had two mortalities among our 95 patients. The first patient was a 20-year old woman with hypertelorism associated with plagiocephaly. She initially did well after surgery; however, on the sixth postoperative day, she developed unilateral orbital edema. She progressed to a coma over the next 48 hours and died. This was before computed tomographic scans were available, and autopsy was refused by the family. Cerebral venous thrombosis was the likely cause of this mortality.

The second death occurred in a 5-year-old boy. He had severe symmetric hypertelorism secondary to a midline cleft. After an otherwise uneventful operation, the patient became unstable over the evening hours. Once again, computed tomography was not available at this time. The patient was taken back to the operating room the next morning, and a right epidural hematoma was noted from the right meningeal artery; however, the patient did not recover and died.

The third serious complication occurred after a medial wall osteotomy. The superior cut along the medial wall lacerated the dura and caused a massive hematoma. Computed tomography was available and a diagnosis was made promptly. The patient was taken back to the operating room and recovered without sequelae. We had one case of infection where the frontal bone flap had to be partially débrided.

Apart from these cases, the other 91 cases had uncomplicated follow-up. Complications are al-

ways to be discussed with the patients or their family, but the two deaths occurred very early in our experience and before the advent of computed tomographic imaging. Munro and Sabatier³ in 1985, after reviewing their cases, noted that there was a decline in complications in the later patients, but remind the readers that, "Major risk of death and infection can occur in any major operation." This salient point should not be disregarded.

DISCUSSION

Mobilization of the orbits is a spectacular operation that has tremendous appeal to the craniofacial surgeon. The questions regarding this operation that remain unanswered are many: Is it dangerous? Is it detrimental to facial growth? What is the best age at which to perform a correction? In addition, other questions that are salient to families persist, such as what result to expect, and whether it is possible to obtain a truly "normal" appearing patient.

Mulliken et al. studied 19 cases of hypertelorism that were corrected using the box osteotomy technique.⁴ Their conclusion was that patients with an interorbital distance greater than 35 mm are more likely to relapse over 5 mm than the 30- to 34-mm (moderate) hypertelorism group. In their series, age at the time of surgery did not play a role in the quality of the result. They recommend postponing surgery until adolescence unless psychosocial reasons supersede.

McCarthy et al. studied 20 patients that were operated on at or younger than 5 years at New York University Medical Center.⁵ They concluded that operating on hypertelorism patients at the

age of 5 years produced stable and satisfactory results. There was a slight increase in the interorbital distance with time that corresponded with normal facial growth,¹¹ and only 25 percent of patients required secondary bone grafts.

Kawamoto et al. reported their experience with 21 patients with hypertelorism and associated craniosynostosis. Eight of their patients had plagiocephaly, whereas 13 had brachycephaly.⁶ They concluded that 5 years of age, when the permanent incisors have erupted, was a suitable time at which to perform the hypertelorism correction.

The Sobrapar group from Brazil (Raposo-Amaral et al.⁷) concluded in their long-term series of 22 patients that there is a difference in the result between patients who were operated on before or after 8 years of age. Results were noted to be better in the older age group, with less relapse. Relapse was especially noted in a group of patients who were operated on at the age of 3. Their patients who were operated on at or after the age of 5 had improved long-term results.

Age at Surgery

We think that one should not operate too early. We attempted two corrections at an early age in patients with frontonasal dysplasia with associated brachycephaly and hypertelorism. At 6 months of age, we mobilized the medial walls toward the midline at the time of the fronto-orbital advancement. In both cases, the medial walls widened again and the hypertelorism recurred and in fact was even worse. A reoperative box osteotomy was performed at 5 years of age and resulted in an excellent outcome.

Therefore, we wait until 5 years of age to correct hypertelorism. This allows for a stronger facial skeleton and improved results. We do not believe there is any significant advantage to waiting until the patient is 8 years old in terms of the facial skeleton's ability to maintain its corrected position. The main argument for operating at this age is to have the child appearing as normal as possible before entering school. At 5 years of age, the central incisors have erupted and a facial bipartition can be performed without fear of injury to the permanent tooth buds. A box osteotomy may also be performed using a high infraorbital horizontal osteotomy. The level at which this osteotomy is performed does not affect unerupted tooth buds. We conceded that results, especially regarding the nose, are more stable if one waits until adolescence; however, the psychological aspect of beginning school with a corrected appearance outweighs that concern.

Considerations for Growth

Does an early operation predispose the patient to midface growth disturbance? We have noted 10 maxillas that could be classified as recessed in the group of patients younger than 8 years of 63 patients who were correctable with orthodontics or surgery. Four of those patients required a Le Fort I osteotomy to advance the maxilla. From our earlier section on secondary operations, our Le Fort I rate was 9 percent in this group. In the group of patients older than 8 years, our Le Fort I rate was 11 percent. As one may appreciate, there is hardly any difference when compared by age of operation.

We have attempted to establish whether there was a correlation between midline resection including the septum and maxillary retrusion.²⁴ Nine patients with resection of the septum had maxillary retrusion, whereas when we kept the septum, all but one patient had normal maxillary growth.

Considerations for the Nose

Regarding the nose, there is no doubt that medial excision followed by bone grafting the dorsum produces in most patients restricted growth of the nose. This requires correction in most cases by a secondary bone graft. This is especially true in male patients. If the shape of the medial part of the nose is normal, it is better to perform paramedian osteotomies and leave the septum and nasal dorsum intact. In most cases, this is not possible because the medial nasal skeleton is so distorted that it has to be resected.

Discussion of nasal reconstruction is very important. In most cases, resection of the central portion of the nose is necessary, including the bifid septum. As the medial walls of the orbit are brought together, the nose is reconstructed using a cranial bone graft. The graft must be fixed rigidly. We use wires passed through the medial orbital walls for fixation of the bone graft. Our reason for avoiding plates or screws is that, in our experience, they often are palpable. Resorbable plates may present an alternative; however, their rigidity for this application is not established. When the tip of the nose is bifid, an open approach is used to narrow the tip by suturing the alar cartilages together over the tip of the bone graft.

Considerations for Excess Skin

There is always excess skin in the midline following medialization of the orbits. Tessier et al. initially used a midline incision¹ from the coronal

incision to the tip of the nose. This provided excellent exposure and allowed for resection of abundant tissue. The drawback to this technique is that it left a very long and visible scar in the frontal region and into the hairline. The scar quality on the forehead is rather unpredictable. In our experience, if the scar is terminated in the glabella and sutured well without tension, this is a very acceptable scar (Figs. 6 and 10). We try to avoid this excision if possible by raising the dorsum of the nose and applying fibrin glue to the underlying nasal skeleton.²¹ We augment this fixation by using transnasal stitches fixed with a bolster and a plaster of Paris cast. However, in some cases, none of these techniques can accommodate the skin redundancy and a skin excision is performed. Our long-term follow-up shows that this is often the best solution for this problem.

Orbital Correction and the Hypertelorism Index

Another important point to discuss is whether, after correction, the intercanthal distance is maintained with time. It has been proposed that an initial good result may progressively deteriorate secondary to ethmoid air space development. Examination of our series indicates that if the initial result was deemed to be good with a normal intercanthal distance, it tends to remain well corrected. If there is undercorrection initially, that result tends to persist. This finding is not correlated to the patient's age at the time of operation. When we say, "initial" result, we do not mean the

on-table appearance of the patient, but the result observed at least 1 month postoperatively. If the intercanthal distance is good at that time, it will remain that way, in our experience.

By using the hypertelorism index in a series of 28 patients who met criteria, we are able to show that there is not only maintenance of the desired result but also an improvement with time of the result as facial growth reestablishes more favorable proportions. This, of course, applies only to cases where our initial result was deemed to be good (Fig. 7).

Regarding the final result, we were able to evaluate, using our hypertelorism index, 28 patients with at least 10 years of follow-up (mean, 19 years; range, 15 to 31 years) who were operated on at an early age. Seventeen of those were considered to be Whitaker category I patients,¹⁸ with good correction of their hypertelorism. With the help of various touchup operations to enhance the quality of the outcome, including rhinoplasty, genioplasty, canthopexy, epicanthal fold correction, and others, these children could be considered to appear normal (Figs. 4 through 6, 8, and 9). The quality of their outcomes was not correlated to the severity of hypertelorism. Many patients had very severe hypertelorism and their result was judged to be very good. Nevertheless, it is not uncommon to have some slight interorbital widening (Figs. 6, 8, and 9). The most spectacular clefts may have a somewhat disappointing result because of the soft-tissue problems rather than the skeletal problems (Fig. 10).

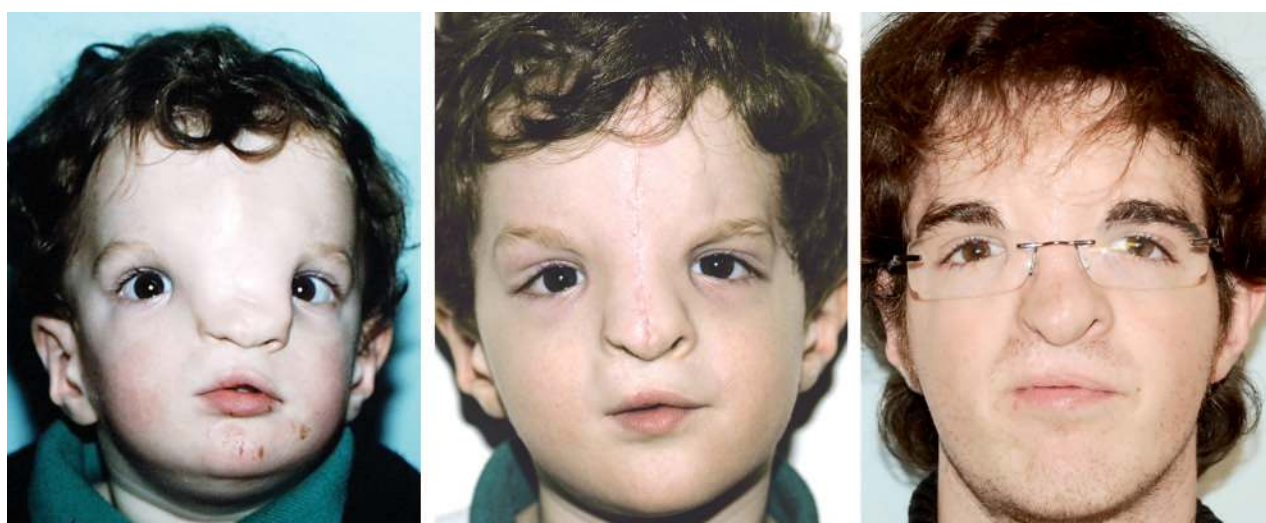

Fig. 10. (Left) At 1 year of age, this patient showed a major hypertelorism associated with a cleft lip, which had undergone operation. (Center) The patient is shown at 6 years after bipartition with bone graft and medial skin excision. (Right) At age 20 years, after revision of the nose with a dorsal incision through the scar, the patient is well inserted and refuses the epicanthal fold correction because his glasses hide the skin excess.

We have not included in this study the hypertelorisms of the frontoencephalocele and patients with Apert syndrome. They will be analyzed in another article.

Choice of Technique

After having initially described the box osteotomy of the orbits,^{1,2} Tessier enthusiastically advocated the facial bipartition approach to treatment.¹⁵ He even came to believe that the box osteotomy was an obsolete operation. We do not agree with that. There are many cases, in our experience, where the patient is best served with a box osteotomy. One has to carefully consider the occlusion of the patient before making a determination of what type of procedure the patient should receive. If the maxilla is narrow with a V-shaped arch or high palate along with oval orbits, this is an excellent indication for a facial bipartition because it will widen the maxillary dental arch and correct the orientation of the orbits (Fig. 2). However, if the occlusion is well aligned and the orbits are of reasonably normal shape, the box osteotomy is the procedure of choice to provide good correction while maintaining the patient's occlusion. The horizontal cut below the orbits is made high to avoid the tooth buds (Fig. 1).

Obtaining correct and stable positioning of the orbit after mobilization is crucial for obtaining good results. After initially simply bringing the orbits together below the frontal bone flap,^{1,2,25} Tessier decided to keep a transverse frontal bandeau just cephalad to the orbital boxes to allow for firm anteroposterior repositioning.²⁶ Since 1986, we have instead used two lateral spurs of frontal bone for fixating the construct. This pattern of craniotomy also allows for easier access to the cranial base¹⁴ (Figs. 1 and 2). We thought it was our idea; however, during our literature review for this article, we found that in 1985 Caronni described this pattern in Rome. Also, the same idea was illustrated by Tulasne²⁴ while working with Tessier, and by Psillakis.²⁷ We feel it is important to note that our technique involves a much longer lateral spur that approaches the middle of the orbits. This allows for good lateral contact with the orbits after medial mobilization. Nevertheless, this emphasizes the principle that one has a good chance of finding a predecessor if one looks hard enough into an idea that one thinks is novel and interesting.

Our observation that a good initial result will be stable with time regardless of the severity of the deformity raises the question of the quality of the initial mobilization and fixation in cases where relapse occurs. We believe that nothing less than

complete mobilization of the orbits without tension on the medialization is essential to obtain a long-term stable correction.

CONCLUSIONS

Our study of our experience with 95 patients brings several closing points to mind. First, the number of serious complications with this procedure is very low if performed by an experienced team. Computed tomography has become invaluable in early detection of serious problems. Second, this operation may be performed before school age (around 5 years) safely, with limited sequelae on facial growth. It is better to accept a small revision for the patients than subject them to the psychosocial issues associated with beginning school with such deformities. Third, if the first operation achieved a good correction of the orbits, one can expect a normal appearance of the orbits at skeletal maturity. Fourth, results obtained with hypertelorism correction do not deteriorate with growth. If the result is good after swelling has decreased, it will remain good. In addition, there is usually an improvement in the hypertelorism appearance in previously treated adults when compared with the initial result in childhood. This point is the most important information we draw from our evaluation of this series (Fig. 7). As Tessier stated, the nasal and canthal deformity poses a greater technical challenge than the osseous hypertelorism correction.¹⁵

Daniel Marchac, M.D.
Plastic Surgery Office
130 Rue de la Pompe
75116 Paris, France
danielmarchac@hotmail.com

PATIENT CONSENT

Patients provided written consent for the use of their images.

REFERENCES

1. Tessier P, Guiot G, Rougerie J, Delbet JP, Pastoriza J. Osteotomies cranio-naso-orbito-facial osteotomies: Hypertelorism (in French). *Ann Chir Plast.* 1967;12:103–118.
2. Tessier P. Experiences in the treatment of orbital hypertelorism. *Plast Reconstr Surg.* 1974;53:1–18.
3. Munro IR, Sabatier RE. An analysis of 12 years of cranio-maxillofacial surgery in Toronto. *Plast Reconstr Surg.* 1985; 76:29–35.
4. Mulliken JB, Kaban L, Evans C, Strand RD, Murray JE. Facial skeletal changes following hypertelorism correction. *Plast Reconstr Surg.* 1986;77:7–16.
5. McCarthy JG, La Trenta GS, Breitbart AS, Zide BM, Cutting CB. Hypertelorism correction in the young child. *Plast Reconstr Surg.* 1990;86:214–225; discussion 226–228.

6. Kawamoto HK, Heller JB, Heller MM, et al. Craniofrontonasal dysplasia: A surgical treatment algorithm. *Plast Reconstr Surg.* 2007;120:1943–1956.
7. Raposo-Amaral CE, Raposo-Amaral CM, Raposo-Amaral CA, Chahal H, Bradley JP, Jarrahy R. Age at surgery significantly impacts the amount of orbital relapse following hypertelorism correction: A 30 year longitudinal study. *Plast Reconstr Surg.* 2011;127:1620–1630.
8. Greig DM. Hypertelorism: A hitherto undifferentiated congenital craniofacial deformity. *Edinburgh Med J.* 1924;31:560–593.
9. Tessier P. Orbital hypertelorism: I. Successive surgical attempts, material and methods: Causes and mechanism. *Scand J Plast Reconstr Surg.* 1972;6:135–155.
10. Converse JM, Ransohoff J, Mathews ES, Smith B, Molenaar A. Ocular hypertelorism and pseudohypertelorism: Advances in surgical treatment. *Plast Reconstr Surg.* 1970;45:1–13.
11. Morin JD, Hill JC, Anderson JE, Grainger RM. A study of growth in the interorbital region. *Am J Ophthalmol.* 1963;56:895–901.
12. Sarnat BG, Bradley JP. The upper face and orbit: Clinical considerations. In: *Craniofacial Biology and Craniofacial Surgery.* London: World Scientific; 2010:335–353.
13. van der Meulen J. Medial faciotomy. *Br J Plast Surg.* 1979;32:339–342.
14. Marchac D, Renier D. Congenital craniofacial malformations. In: Youmans JR, ed. *Neurological Surgery.* Vol. 2. Philadelphia: Saunders; 1996:1012–1034.
15. Tessier P. Facial bipartition: A concept more than a procedure. In: Marchac D, ed. *Proceedings of the First International Congress of the International Society of Cranio-Maxillo-Facial Surgery.* Berlin: Springer-Verlag; 1987:217–245.
16. Tessier P. Anatomical classification facial, cranio-facial and lateral-facial clefts. *J Maxillofac Surg.* 1976;4:69–92.
17. Gunther H. Konstitutionelle Anomalien des Augenabstandes und der Interorbitalbreite. *Virchows Arch Pathol Anat.* 1933;290:373–384.
18. Whitaker LA, Bartlett S, Shut L, Bruce D. Craniosynostosis: An analysis of the timing, treatment, and complications in 164 consecutive patients. *Plast Reconstr Surg.* 1987;80:195–212.
19. Moreira Gonzalez A, Elahi M, Barakat K, Yavuzer R, Brinkmann B, Jackson IT. Hypertelorism: The importance of three-dimensional imaging and trends in the surgical correction by facial bipartition. *Plast Reconstr Surg.* 2005;115:1537–1546.
20. Farkas LG, Munro IR. *Anthropometric Facial Proportions in Medicine.* Springfield, Ill: Charles C Thomas; 1987.
21. Marchac D, Renier D. Fibrin glue in craniofacial surgery. *J Craniofac Surg.* 1990;1:32–34.
22. Marchac D, Greensmith A. Long term experience with methylmethacrylate cranioplasty in craniofacial surgery. *J Plast Reconstr Aesthet Surg.* 2008;61:744–752; discussion 753.
23. Ortiz-Monasterio F. Personal communication; 1990.
24. Tulasne JF. Maxillary growth following total septal resection in teleorbitism. In: Caronni EP, ed. *Craniofacial Surgery.* Boston: Little, Brown; 1985:176–189.
25. Tessier P, Guiot G, Derome P. Orbital hypertelorism: II. Definite treatment of orbital hypertelorism (OR.H) by craniofacial or by extracranial osteotomies. *Scand J Plast Reconstr Surg.* 1973;7:39–58.
26. Tessier P. Le Teleorbitisme. Chirurgie Plastique Orbito-Palpebrale. In: *Rapport Societe Francaise d'Ophthalmologie.* Paris: Masson; 1977:305–326.
27. Psillakis J. Surgical treatment of hypertelorbitism. In: Caronni EP, ed. *Craniofacial Surgery.* Boston: Little, Brown; 1985:190–199.

e-TOCs and e-Alerts

Receive the latest developments in plastic and reconstructive surgery.

Request the delivery of *Plastic and Reconstructive Surgery's* e-Alerts directly to your email address. This is a fast, easy, and free service to all subscribers. You will receive:

- Notice of all new issues of *Plastic and Reconstructive Surgery*, including the posting of a new issue on the PRS-Online Web site
- Complete Table of Contents for all new issues

Visit www.PRSJournal.com and click on e-Alerts.